



ELSEVIER

Contents lists available at ScienceDirect

Microvascular Research

journal homepage: [www.elsevier.com/locate/ymvre](http://www.elsevier.com/locate/ymvre)

Short Communication

## Dynamic fluorescence imaging of indocyanine green for reliable and sensitive diagnosis of peripheral vascular insufficiency

Yujung Kang<sup>a,b</sup>, Jungsul Lee<sup>a,b</sup>, Kihwan Kwon<sup>c,\*</sup>, Chulhee Choi<sup>a,b,\*</sup><sup>a</sup> Department of Bio and Brain Engineering, KAIST, Korea<sup>b</sup> KI for the BioCentury, KAIST, Korea<sup>c</sup> Department of Cardiology, School of Medicine, Ewha Woman's University, Korea

## ARTICLE INFO

## Article history:

Received 28 May 2010

Accepted 8 July 2010

Available online 15 July 2010

## Keywords:

Peripheral vascular disease

Perfusion

Arterial stenosis

Optical imaging

Indocyanine green

## ABSTRACT

Quantitative measurement of functional tissue perfusion is essential for early diagnosis and proper treatment of peripheral arterial occlusive disease (PAOD). We have previously demonstrated that dynamic imaging of near-infrared fluorophore indocyanine green (ICG) can be a noninvasive and sensitive tool to measure tissue perfusion. In the present study, we investigated the clinical efficacy of ICG perfusion imaging method for the diagnosis of PAOD. Total nineteen PAOD patients and age-matched controls ( $n = 10$ ) were evaluated for lower extremity tissue perfusion using ICG perfusion imaging. The perfusion rates of the lower extremities with severe PAOD ( $n = 25$  legs,  $16.6 \pm 8.3\%/min$ ) were significantly lower than those of normal controls ( $38.1 \pm 17.3\%/min$ ,  $p < 0.001$ ). In cases of mild PAOD, the perfusion rates ( $n = 11$  legs,  $18.3 \pm 10.3\%/min$ ) were also significantly lower compared to the control; while the conventional ankle-brachial index (ABI) test failed to detect mild functional impairment. These results collectively indicate that ICG perfusion imaging can be a very effective tool for diagnosis of PAOD with a superior efficacy in comparison to conventional ABI test.

© 2010 Elsevier Inc. All rights reserved.

## Introduction

Peripheral vascular disease (PVD) has been defined as lower extremity arterial atherosclerosis because most PVD occurs in the major arterial segments of aortoiliac, femoropopliteal, and tibio-peroneal arteries. This syndrome encompasses a wide range of diseases from asymptomatic arterial narrowing to critical limb ischemia and gangrene (Khan and Shearman, 2005). Hyperglycemia, dyslipidemia, and hypertension are well-known potentially modifiable risk factors for the development of PVD (Adler et al., 2002). Although PVD is prevalent in the primary care setting, it has also been unrecognized and undertreated. However, based on an association with fatal cardiovascular diseases, high-risk patients have been recommended to receive a periodic medical checkup for PVD in the primary care setting (Stein et al., 2006).

Diagnostic methods presently used include the ankle brachial index (ABI), plethysmography, and angiography by X-ray or computed tomography (CT), all of which have limitations. The ABI is highly sensitive and specific for diagnosing PVD in patients with severe arterial stenosis, but the utility of the ABI in patients with less severe stenosis and calcified vessels is questionable (Stein et al.,

2006). Plethysmography, applying the strain-gauge technique, detects pulsatile pressure changes in a nearby artery; therefore, the arterial pressure measured by plethysmography is not a reliable index of arterial flow in cases of abnormal vascular impedance. X-ray and CT angiography can only visualize the vessel lumen, and not the wall, and cannot assess the end-organ effects of peripheral artery occlusive disease (PAOD) (Kramer, 2007). Because of the procedure invasiveness, arteriography is usually reserved for patients with occult symptoms sufficient to make them surgical candidates and is not usually required for an early PAOD diagnosis. Diagnostic modalities that allow study of progression and regression of PVD are clearly needed. The ability to assess functional tissue perfusion will be ideal for the periodic checkup, early diagnosis, and adequate treatment of PVD.

Near-infrared (NIR) fluorescence optical imaging has been studied as a noninvasive and non-ionizing diagnostic modality for in vivo imaging of the vasculature and estimating functional perfusion. Optical imaging as a screening method has several advantages: no or minimal invasiveness, low cost, safety, ease of use, and bedside assessment (Cheng et al., 2005; Frangioni, 2003; Keller et al., 2001). We previously developed an ICG perfusion imaging method that employs time-series planar NIR fluorescence imaging and analyzes modeling of spatiotemporal dynamics to assess perfusion in the lower extremities (Kang et al., 2009a, 2009b, 2010). In this study, we performed a pilot clinical study to validate the efficacy of this method on the diagnosis of mild as well as severe PAOD.

\* Corresponding authors. Kwon is to be contacted at Department of Cardiology, Ewha Woman's University, Seoul 158-710, Korea. Fax: +82 2 2650 2640. Choi, Department of Bio and Brain Engineering, KAIST, Daejeon 305-751, Korea. Fax: +82 42 350 4380.

E-mail addresses: [kankadin@ewha.ac.kr](mailto:kankadin@ewha.ac.kr) (K. Kwon), [cchoi@kaist.ac.kr](mailto:cchoi@kaist.ac.kr) (C. Choi).

**Table 1**  
Demographics of patients enrolled in the study.

Arterial stenosis	Less than 20% <i>n</i> = 10 (20 legs)	20–50% <i>n</i> = 8 (11 legs)	More than 50% <i>n</i> = 16 (25 legs)
Age, years	59.6 ± 8.2*	66.5 ± 8.7*	68.7 ± 9.9*
Median	61	68	71
Gender, male/female	2/8	5/3	12/3
Risk factors			
HTN (mean duration)	2 (4)	2 (3.5)	5 (5)
DM (mean duration)	–	–	3 (10)
Smoking	–	–	1
Dyslipidemia	1	–	–

\* $F_{2,31} = 3.154$ ,  $p = 0.057$  by ANOVA test.

## Materials and methods

### Subjects

All protocol, survey, and consent forms were approved by the Institutional Review Board of Ewha Woman's University Mokdong Hospital. Written informed consent was obtained from all subjects. Twenty-nine subjects were recruited for the analysis of perfusion rates of the lower extremities to test the efficacy of ICG perfusion imaging for the diagnosis of PAOD. PAOD was defined on lower extremities by CT angiography as a diameter reduction of >50% in the major peripheral arteries, and leg showing diameter reduction less than 20% was defined as a normal; leg with arterial stenosis between 20% and 50% of in the major peripheral arteries, as a mild PAOD. Twenty-five of the PAOD legs were recruited from nine patients with bilateral stenosis and seven patients with unilateral stenosis (arterial stenosis more than 50% in only one leg), and 11 mild-PAOD legs were collected from 3 subjects with bilateral and 5 patients with unilateral mild stenosis. Finally, twenty of normal legs were examined from 10 age-matched subjects (Table 1). Lower extremity CT angiography, ABI, and the ICG perfusion imaging test were performed in all subjects.

### Lower extremity CT angiography

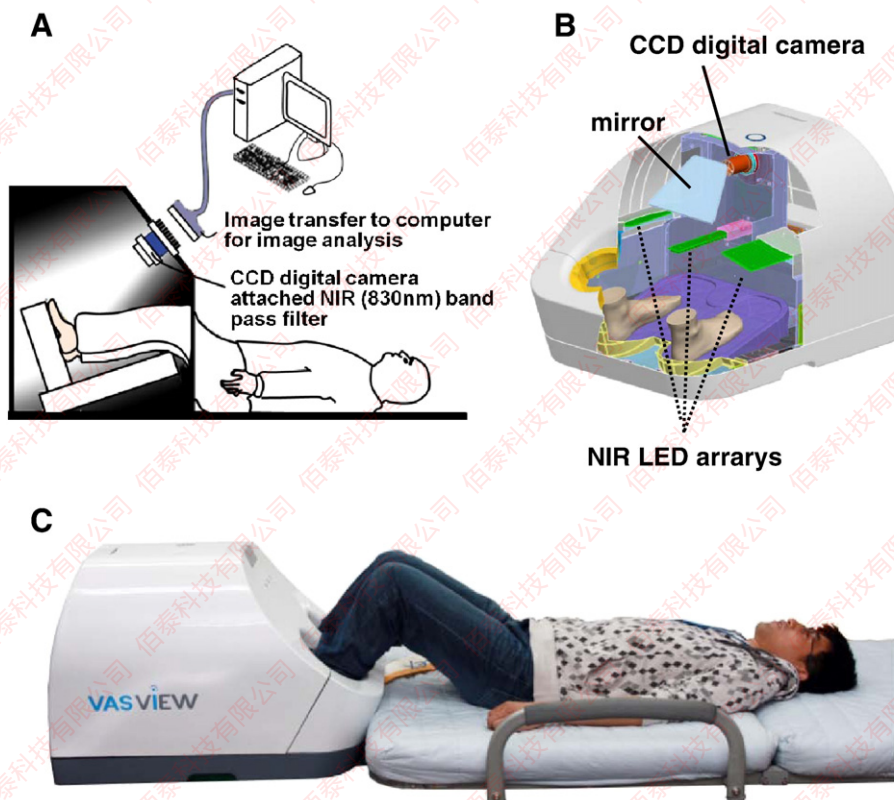
Lower extremity CT angiography, ABI, and the ICG perfusion imaging test were performed in all subjects. CT angiography was performed with a 16-MDCT scanner (SOMATOM Sensation; Siemens Medical Solutions, Erlangen, Germany), and volume data sets were acquired with  $12 \times 0.75$  mm collimation, a gantry rotation time of 420 ms, a table feed of 2.8 mm per  $360^\circ$  rotation, and an effective tube current-time product of 400 mAs at a tube voltage of 120 kV. An 18-gauge catheter was placed into the antecubital vein, and 120 ml of nonionic contrast material (Iohexol, Omnipaque 300, Nycomed; Amersham, Princeton, UK) was injected at 4 ml/s. CT scans were obtained from above the iliac bifurcation to the feet. Postprocessing for CT angiography resulted in images rotated over  $360^\circ$  for the aortoiliac, femoropopliteal, and tibial arteries using commercially available cardiac reconstruction software (Syngo, version A50A; Siemens Medical Solutions). Two doctors with extensive experience interpreting CT angiograms evaluated all images for arterial stenosis and assessed the degree of stenosis.

### Ankle brachial index (ABI)

After remaining supine for 5–10 min, blood pressures were recorded in both brachial arteries and in the dorsalis pedis and posterior tibial arteries (VasoGuard P84; SciMed Ltd., Bristol, UK). The ABI was calculated for each leg by dividing the highest ankle systolic pressure by the highest brachial systolic pressure. Generally, an  $ABI < 0.9$  was interpreted as legs with PAOD.

### ICG perfusion imaging

We recently developed a novel optical imaging-based technology for translating ICG time-series images into a quantitative perfusion rate (%/min), which was defined as the fraction of blood exchanged in the vascular volume per minute (Kang et al., 2009a, b, 2010). Fig. 1 illustrates



**Fig. 1.** ICG perfusion imaging system. (A and B) Diagram of the imaging system. (B) Outside view of the system. (C) Capturing an ICG serial imaging for perfusion analysis.

an ICG fluorescence imaging system manufactured by Vieworks Corporation (Seongnam, Gyeonggi-do, Korea). After remaining supine for 5–10 min, 120 serial images ( $748 \times 518$  pixels) of both feet were taken at 5-s intervals for 600 s after an intravenous bolus injection of ICG (0.16 mg/kg) for time-series analysis of ICG fluorescence. The perfusion rate was calculated using nonlinear regression and differential evolution methods as described previously (Kang et al., 2010).

#### Statistical analysis

Data are expressed as the mean  $\pm$  SD. Statistical significance was assessed by Student's two-tailed *t*-tests for analysis of the PAOD and normal control. Correlation between the perfusion rate and the ABI was analyzed with an ANOVA and Bonferroni post hoc test on the groups of mild-PAOD, PAOD and normal control. The difference between samples was considered statistically significant if the *p* value was less than 0.05.

#### Results and discussion

The perfusion rates of normal legs were significantly higher ( $38.1 \pm 17.3\%/min$ ) compared to those of the PAOD legs ( $16.6 \pm 8.3\%/min$ ; Fig. 2A). Setting the value of 24.4%/min perfusion rate

as a cutoff, this optical approach predicted the presence of PAOD with a sensitivity of 0.92 and a specificity of 0.90 with an area under the ROC curve of 0.895 (95% confidence interval, 0.79 to 1.0) for the angiographically documented PAOD (Fig. 2B). Because our novel optical method detects functional perfusion impairment rather than structural abnormalities, this method might be useful not only for confirming obvious occlusive cases but also for detecting mild impairment, especially in the early stages of atherosclerotic changes. To test this idea, the perfusion rates of lower extremities from 8 subjects with asymptomatic PAOD were evaluated and compared with those of normal and severe PAOD legs. As expected, the perfusion rates of mild PAOD cases were significantly lower compared to those of normal control ( $18.3 \pm 10.3\%/min$ ,  $F_{2,53} = 18.0$ ,  $p < 0.001$  by ANOVA test) (Fig. 2C left panel). Although the ABIs of mild-PAOD, PAOD and normal groups were significant differences ( $1.2 \pm 0.1$ ,  $1.0 \pm 0.2$ ,  $0.6 \pm 0.2$ , respectively;  $F_{2,53} = 57.7$ ,  $p < 0.001$  by ANOVA test), there was no significant difference in the ABIs between normal and mild-PAOD legs ( $p = 0.14$  by Bonferroni post hoc test, Fig. 2C right panel).

Consistent with a previous report (Lijmer et al., 1996), the ABI could detect PAOD legs as well as ICG perfusion imaging method.

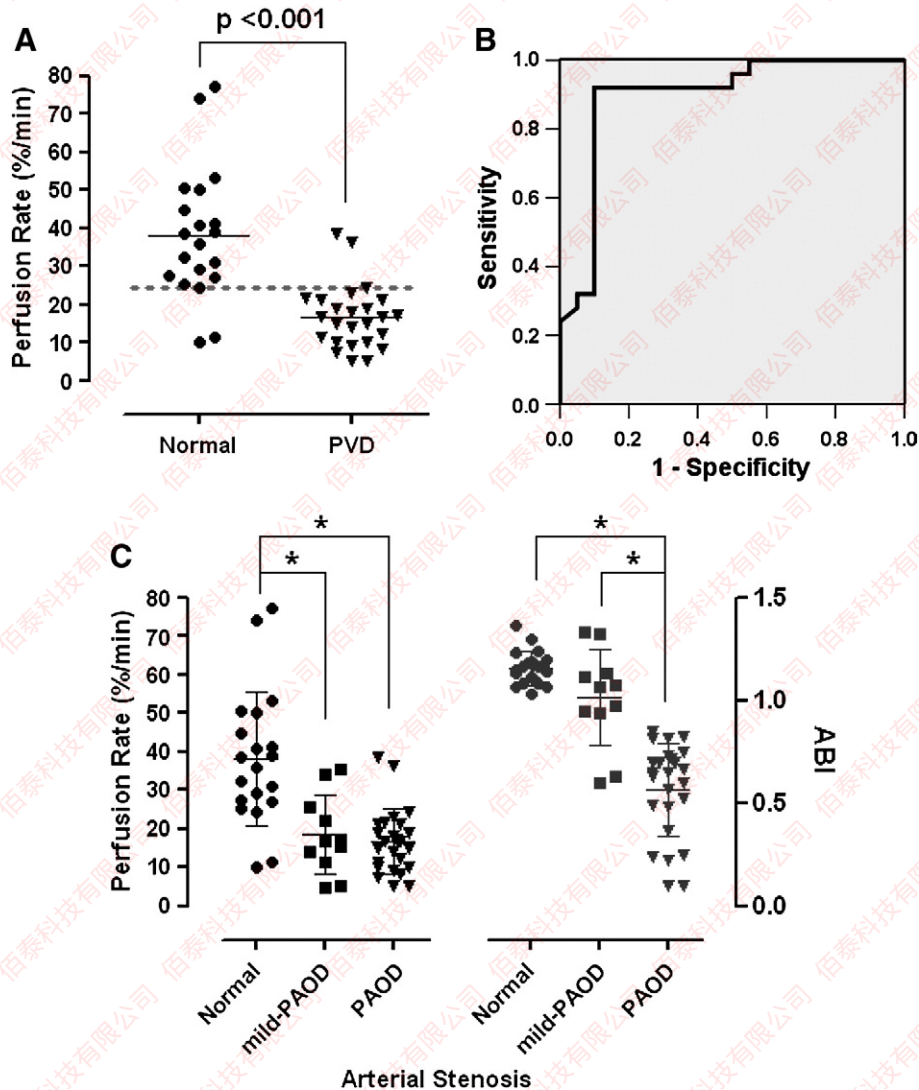


Fig. 2. The performance of the perfusion rate to discriminate PAOD legs from normal legs. (A) Perfusion rates from the PAOD and Normal legs. Each dot represents one leg. The gray dashed line indicates a cutoff value for diagnosis of PAOD. *p* Value was evaluated by Student's *t*-test. (B) ROC curve of the perfusion rate to diagnose PAOD legs. The ideal criterion was defined as the white point on the ROC curve. (C) Perfusion rates and ABIs of the mild-PAOD, PAOD and normal groups. \* $p < 0.001$  by Bonferroni post hoc test.



On the contrary, this conventional method failed to differentiate mild cases of PAOD from a normal group; while the ABI has been widely applied to detect the functional decline in peripheral vasculature due to its sensitivity and noninvasiveness (McDermott et al., 2009). Despite these advantages, the ABI shows poor discriminative power in distinguishing mild and moderate degrees of stenosis (McDermott et al., 2005), as well as in providing diagnostic information, particularly in patients with diabetes and limb claudication (Lindner et al., 2008). Although large population studies have demonstrated a significant correlation between the ABI and clinical symptoms, normal ABIs are commonly encountered in patients with symptomatic PAD (Wang et al., 2005). Considering the high sensitivity of ICG perfusion imaging for detection of mild functional impairments, we suggest a combined use of the ABI and perfusion imaging for a complementary diagnosis of various stages of perfusion impairment.

Although the small number of patients had been enrolled in the current study, our pilot clinical trial clearly demonstrated that this novel dynamic optical imaging combined with modeling can provide highly reliable and quantitative estimates of peripheral tissue perfusion sensitive enough for diagnosis of mild cases of PAOD. This observation on efficacy of ICG perfusion imaging test prompts us to pursue a large-scale study to unveil the role of various risk factors such as metabolic abnormalities on peripheral vascular insufficiency.

#### Acknowledgments

We thank Dr. D. Kim (Department of Cardiology, School of Medicine, Ewha Woman's University) for help with the clinical trial. This work was supported by the Korea Healthcare Technology R&D

Project (A091258), Ministry for Health, Welfare and Family Affairs of the Republic of Korea.

#### References

- Adler, A.I., et al., 2002. UKPDS 59: hyperglycemia and other potentially modifiable risk factors for peripheral vascular disease in type 2 diabetes. *Diab. Care* 25, 894–899.
- Cheng, Z., et al., 2005. Near-infrared fluorescent RGD peptides for optical imaging of integrin  $\alpha v \beta 3$  expression in living mice. *Bioconjugate Chem.* 16, 1433–1441.
- Frangioni, J.V., 2003. In vivo near-infrared fluorescence imaging. *Curr. Opin. Chem. Biol.* 7, 626–634.
- Kang, Y., et al., 2009a. Quantitative analysis of peripheral tissue perfusion using spatiotemporal molecular dynamics. *PLoS ONE* 4, e4275.
- Kang, Y., et al., 2009b. Application of novel dynamic optical imaging for evaluation of peripheral tissue perfusion. *Int. J. Cardiol.* doi:10.1016/j.ijcard.2008.12.166.
- Kang, Y., et al., 2010. Assessment of peripheral tissue perfusion by optical dynamic fluorescence imaging and nonlinear regression modeling. *Proc. SPIE* 7548 75483L-75483L-13.
- Keller, E., et al., 2001. Estimation of cerebral oxygenation and hemodynamics in cerebral vasospasm using indocyanine green dye dilution and near infrared spectroscopy: a case report. *J. Neurosurg. Anesthesiol.* 13, 43–48.
- Khan, O.A., Shearman, C., 2005. Is there a fetal origin of peripheral vascular disease? *Heart* 91, 869–870.
- Kramer, C.M., 2007. Peripheral arterial disease assessment: wall, perfusion, and spectroscopy. *Top. Magn. Reson. Imaging* 18, 357–369.
- Lijmer, J.G., et al., 1996. ROC analysis of noninvasive tests for peripheral arterial disease. *Ultrasound Med. Biol.* 22, 391–398.
- Lindner, J.R., et al., 2008. Limb stress-rest perfusion imaging with contrast ultrasound for the assessment of peripheral arterial disease severity. *JACC Cardiovasc. Imaging* 1, 343–350.
- McDermott, M.M., et al., 2009. Associations of borderline and low normal ankle-brachial index values with functional decline at 5-year follow-up: the WALCS (Walking and Leg Circulation Study). *J. Am. Coll. Cardiol.* 53, 1056–1062.
- McDermott, M.M., et al., 2005. Ankle-brachial index and subclinical cardiac and carotid disease: the multi-ethnic study of atherosclerosis. *Am. J. Epidemiol.* 162, 33–41.
- Stein, R., et al., 2006. Limitation of the resting ankle-brachial index in symptomatic patients with peripheral arterial disease. *Vasc. Med.* 11, 29–33.
- Wang, J.C., et al., 2005. Exertional leg pain in patients with and without peripheral arterial disease. *Circulation* 112, 3501–3508.